Retina Problem Solving

Brendan Girschek, MD, FRCSC, FACS
Vitreoretinal Surgery
Bluegrass Retina Consultants
Lexington, Kentucky

What are our roles?

- Your role:
  - The front-line providers
  - Have already developed a excellent working relationship with the patient
- My role:
  - To help manage retinal problems and provide a second opinion regarding any potential retinal emergency
  - I am never bothered by calls or texts asking to evaluate a symptomatic PVD or evaluate a sudden decrease in vision in a patient with AMD or retinal vein occlusion
- Two exams are better than one
  - I want for you to feel that I can help take some of the burden away from you in diagnosing and/or managing retinal issues your patients may have

Timing of Referrals

- Immediately (pt NPO):
  - endophthalmitis
  - retinal detachment, macula on
- Within 1 day:
  - retinal break
  - retinal detachment, macula off
  - dense vitreous hemorrhage (no view)
  - severe uveitis
  - wet AMD with heme
  - optic nerve head edema
- Within 1-2 days:
  - wet AMD, RVO w/ either NV or CME
  - mild vitreous hemorrhage (ok view)
  - diabetic vitreous hemorrhage
  - tractional retinal detachment
  - moderate uveitis
- Within 1 week:
  - diabetic macular edema
  - mild uveitis, anterior

What are we concerned about?

- Rule out:
  - Retinal detachment
  - Endophthalmitis
- Anything with sudden loss of vision or profound decrease in vision
- The vitreous/retina can be difficult to examine in the face of hemorrhage, pain or poor cooperation
- When in doubt, call or text!

Vitreous Hemorrhage (VH)

- Symptoms can vary from mild to severe
- Common causes:
  - Retinal tear/detachment
  - Neovascularization from diabetes, vein occlusion
- Rule out:
  - Retinal detachment
- Serial and frequent dynamic B-scans
- Hemorrhage is not toxic to the eye and can be safely observed in most cases

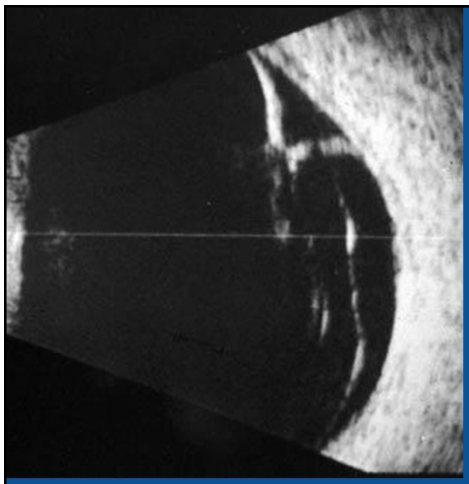

VH, ?RD

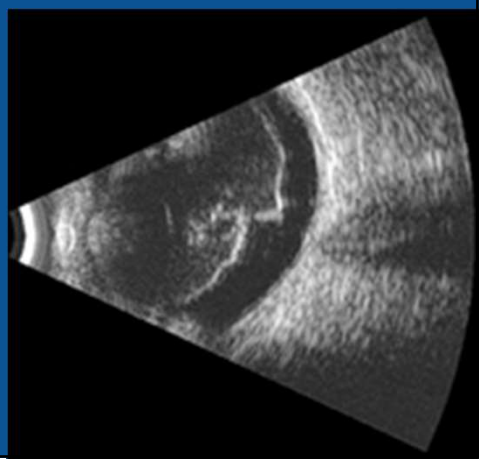

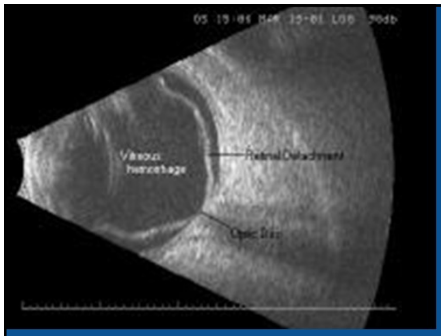

total RD

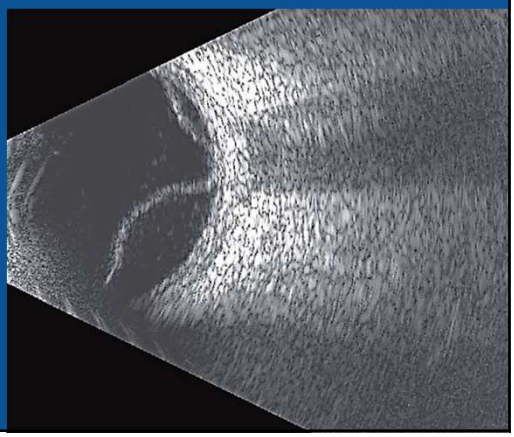

Is there a PVD?

- Absence of PVD will often exclude a retinal break or detachment
- Is there any evidence of posterior ischemia or uveitis in the anterior segment?

Diabetic Retinopathy (DR)

- Indications for treatment include:
  - Clinically-significant macular edema (CSME)
    - Focal laser to MAs; anti-VEGF therapy or Sub-Tenon's Kenalog
  - Diffuse macular edema (DME)

    Intravitreal avastin, targeted peripheral PRP to reduce VEGF-load, intravitreal Ozurdex or PPV/ILM peel if chronic
  - Proliferative diabetic retinopathy (PDR)
    - PRP and intravitreal avastin (knock it down with avastin, keep it down with PRP)
  - Macula-involving tractional retinal detachment (TRD)
    - PPV with cutter delamination of epiretinal membranes

Macular Edema (ME)

- Most common cause of vision loss in DR
- First-line treatment involves monthly injections of intravitreal anti-VEGF with focal laser to individual microaneurysms within areas of ME
  - Micropulse sub-threshold focal laser is revolutionary
- Intravitreal kenalog has short-lived benefits with significant side effect profile not seen with IVA/L/E, prefer sub-tenon's due to reduced cataract/glaucoma concerns
  - Much safer safety profile with Ozurdex implant
- Spectral-domain OCT imaging useful to evaluate response to therapy
- Consider fluoroscein angiography or OCT-A to evaluate for:
  - macular ischemia if suboptimal vision with or without obvious ME
  - Identify microaneurysms that leak to treat with focal laser
  - Perform peripheral targeted PRP to areas of ischemia
    - reduce VEGF load and help treat macular edema

Benefits to treatment of anti-VEGF to reduce foveal exudation

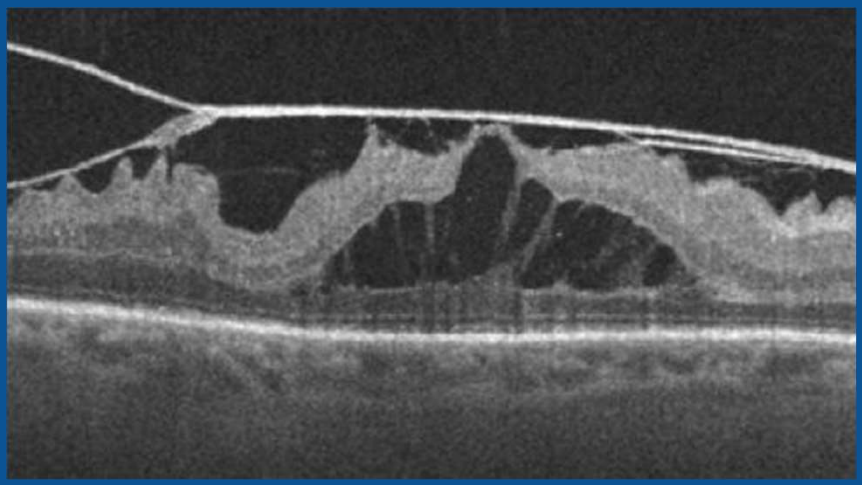

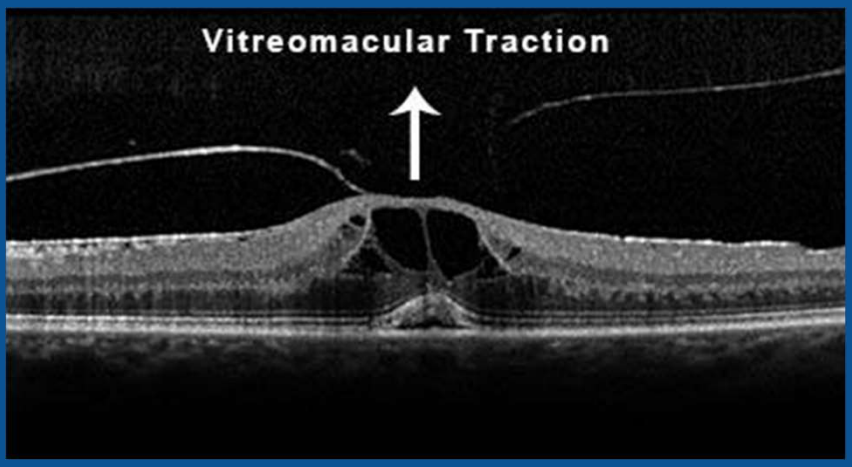
Vitreomacular Traction

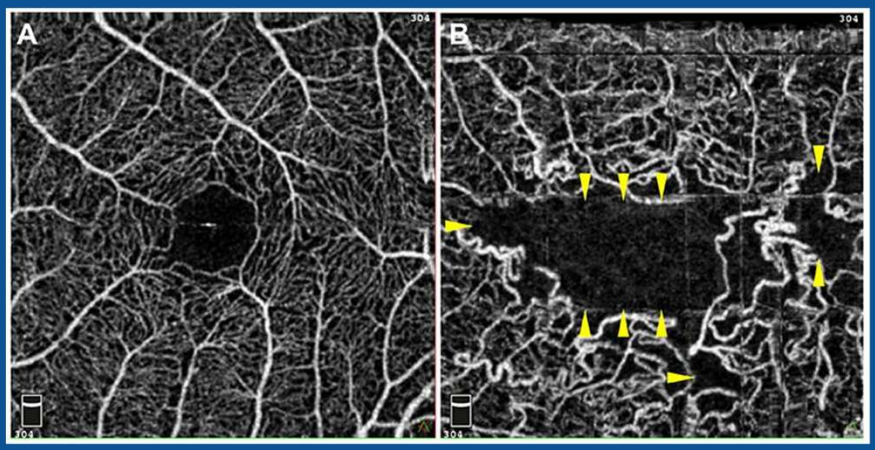
A
B

Proliferative Diabetic Retinopathy

- "Knock it down with avastin, keep it down with laser"
  - IVA/L/E induces vasoconstrictive regression of NV for roughly 1 month
    - Some believe that PDR can be treated exclusively with monthly injections of IVA much like with proliferative ROP
  - Panretinal photocoagulation to areas of non-perfusion at the same visit as IVA (done before injection)
    - If unable to perform PRP due to VH, inject IVA to encourage regression of VH (allow blood to clear while bleeding has ceased)
  - Consider pars plana vitrectomy (PPV) in:
    - Non-clearing VH (perform endo-PRP)
      - how long do you wait?
    - Macula-involving TRD (scissors delamination of epiretinal membrane)
    - Chronic macular edema unresponsive to laser or IVA/L/E (perform ILM peel)

Apply PRP to areas of non-perfusion to minimize reactive macular edema

Retinal Vein Occlusion

- Presents with sudden VA loss with metamorphopsia (macular involvement) +/- VF loss
- Why wait for 3 months?
  –Pre anti-VEGF therapy
- Less conversion to ischemic RVO with early IVL/E
  – IVL and IVE are approved for macular edema associated with RVO; profoundly higher binding affinity for VEGF and preferred over avastin
- Not a true emergency unless associated with neovascular glaucoma
  – Treat with urgent PRP to all ischemic retina and intravitreal anti-VEGF agents

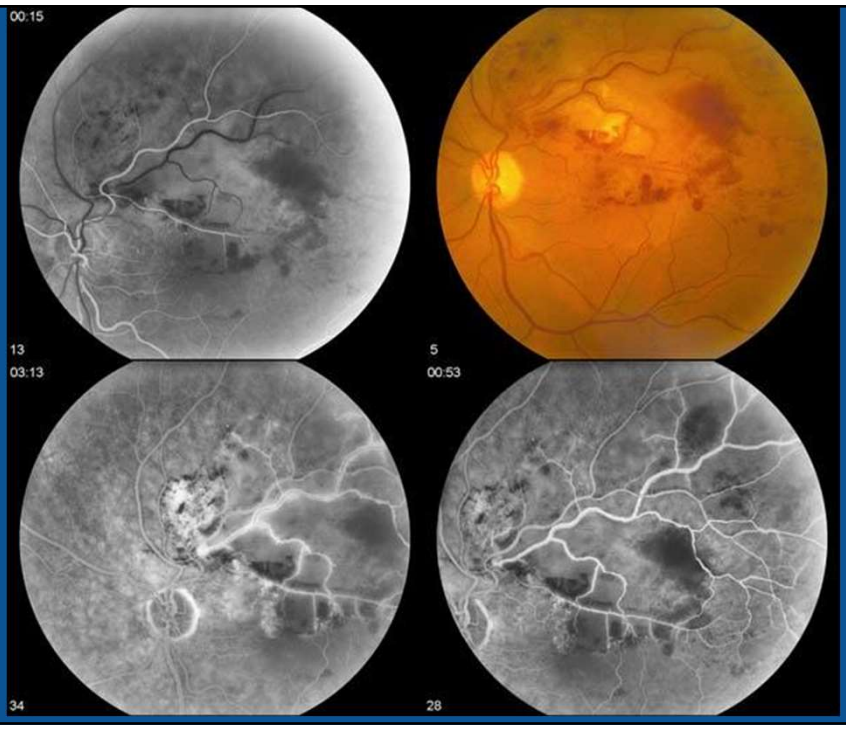

Retinal Vein Occlusion

- Management of RVO-related ME includes anti-VEGF on first visit and every visit (monthly evaluations)
  - Evaluate response with spectral-domain OCT at each visit
  - Timing is critical - patients will worsen if off a few days
- Early treatment with anti-VEGF has been demonstrated to prevent conversion from perfused to non-perfused RVO thereby providing superior outcomes compared to observation or laser
- Ozurdex works well to augment therapy
  - Tease out steroid-response with Durezol

RVO

- Micropulse sub-threshold grid laser has been a welcome addition to the treatment protocol
- If refractory to repeat anti-VEGF and steroids, consider PPV with ILM peel
  - Increased oxygen-carrying capacity of aqueous and allows for “decompression” of edematous macula
  - Unofficial first line treatment for poorly compliant patients especially w/ proliferative disease

Sub-Macular Hemorrhage

- Due commonly to “wet” AMD, less commonly due to angioid streak/choroidal rupture
- Often seen after initial treatment with anti-VEGF agents with bullous PEDs (RPE rip)
- Requires pneumatic displacement with 38gauge cannula, subretinal tPA and gas bubble (face-down positioning)
  - Goal is to displace the hemorrhage inferiorly and away from macula
  - Recommended if hemorrhage is < 2 weeks old
  - Blood under the retina is toxic to photoreceptors (blood above retina is NOT)

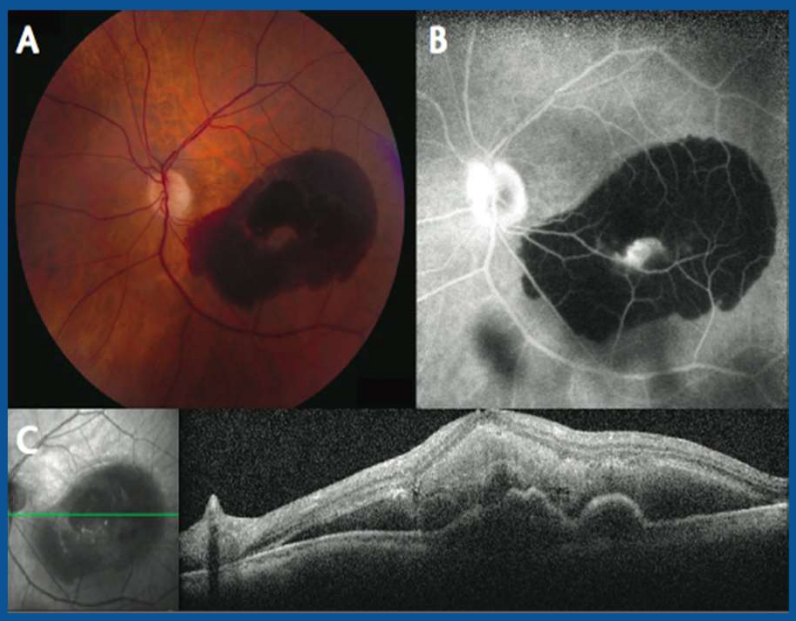

"Wet" Macular Degeneration

- Polypoidal variant (PPCV) offer the best long-term outcomes but requires the most # of injections
  –Slow growing root instead of fast growing weed (RAP)
- Intra-retinal (RAP, type 3) lesions develop the fastest with best response also requiring least no. of injections
- Much better outcomes with rapid treatment (days, not weeks)
  – Want to avoid development of disciform scar in the subretinal space
  – Subretinal fluid (slowly), intraretinal edema (quickly) and heme will resolve with treatment
  – Fibrovascular scar/fibrosis will NOT

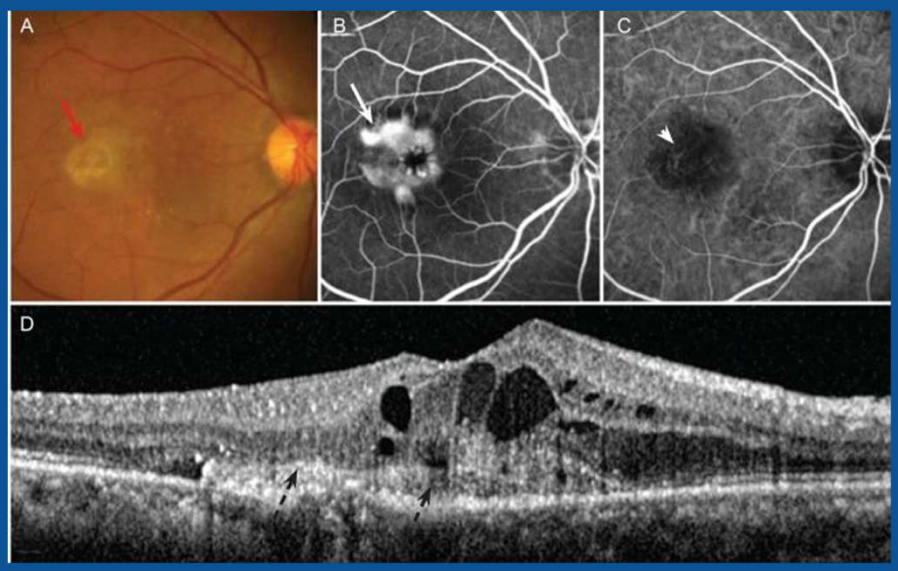
A
B
C
D

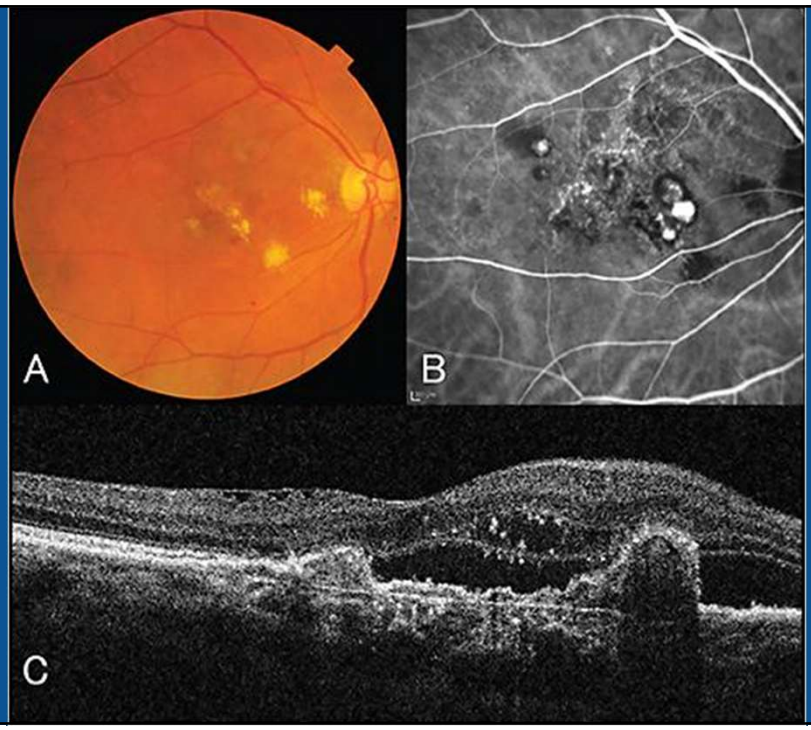
A
B
C

Anti-VEGF in wet AMD

- Most patients will require 3-6 injections before remission with treat & extend w/ close follow-up thereafter
  - Some require more (polypoidal, occult), some less (RAP, classic)
- Important for patients to understand the natural history of the disease and not be discouraged with continued treatment
  - There are many patients who maintain very useful vision after 30+ injections!
  - 95% maintain their level of vision within 3 lines of VA
  - 75% remain stable with regards to VA
  - 40% improve their VA

Management of "Wet" AMD

- "Treat and Extend" is the method I prefer:
  - Treat every 4 weeks with anti-VEGF with spectral-domain OCT and fundus examination until "inactive" (no SRF/CME/SRH)
    - Weekly extensions to 8 weeks then to 12 weeks
    - Should exudation recur, shorten interval and re-attempt T&A after two injections
    - Try to time injections to treat OU when possible
  - Safest approach is to continue monthly injections indefinitely (increased concern with choroidal atrophy leading to progressive geographic atrophy!)
    - followed by 5% of retina specialists
  - Riskiest approach is to treat until dry and then PRN
    - followed by 25% of retina specialists

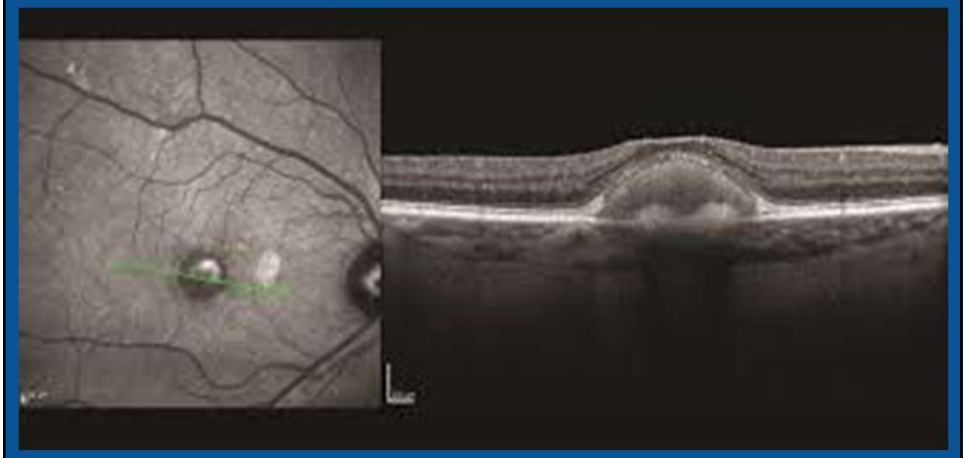

Post-Injection Management

- Post-injection antibiotics have been noted to *not improve incidence of endophthalmitis, creates a situation of resistant "super-bacteria" and is a cost-burden to patient*
- Much of the immediate "burning" or pain after injections is not from the injection but from the 5% betadine used to prep the eye
  - Topical NSAIDS work well but $$
  - frequent pre and post injections PF AFTs are the mainstay
- Timing of endophthalmitis after injections is usually 3-4 days afterwards
  - Very rare occurrence
  - Usually "sterile" or hyperinflammatory if sudden (0-2 days)
    - Reaction to impurity within the batch of Avastin and Eylea (rare with lucentis)
    - Near-total visual recovery is the rule
    - Minimal pain or conjunctival injection, complain of floaters/decr. vision

Initial work-up for AMD

- 90D slit-lamp examination
  - look for retinal hemorrhage, exudates, SRF/PED
- Spectral-domain OCT
  - look for "indirect" evidence of activity of CNV: SRF/CME/RPE thickening or elevation
- Autofluorescence
  - Offers perspective on prognosis of geographic atrophy, not useful in "wet" AMD
- Fluorescein vs ICG
  - Beware of false + w/ vitelliform on FA, ICG time consuming
- OCT-angiography
  - Quick, reliable with low false + in the right

Uveitis

- Need to define that anatomy of inflammation: anterior, intermediate, posterior or pan?
- Is there a history of recent surgery or trauma?

Initial treatment with q1-2h prednisolone 1% or durezol q2-3h along with cycloplegia is preferred in anterior uveitis

- *Drops are NOT effective in treating inflammation posterior to the lens*
  - Require sub-Tenon's kenalog (preferred over intra-vitreal kenalog) or systemic steroids and/or immunomodulatory therapy
  - Can't undo the effects of steroid when injected
  - When in doubt, start oral steroids and perform injection when serology/labs are negative

Cataract Surgery Complications

- Main concern with retained lens fragments is glaucoma
- Elevated IOP often responsive to glaucoma meds (avoid prostaglandins)
- Control inflammation with initially hourly steroid drops (taper when possible) and cycloplegia, rarely require oral prednisone
- I prefer to operate when eye becomes quiet and cornea is clear (can easily wait 2-3 weeks)
- If moderate amount of cortex, minimal inflammation, no glaucoma or lens-cornea touch present, may NOT require vitrectomy

PVD

- Two exams are better than one
  - I would be happy to examine any symptomatic PVD
- Urgent referral for sudden showering of “thousands” of floaters, persistent flashes or visual field loss
- 3 F’s: flashes, floaters and/or field defects
- Will evaluate again 1 month after initial exam; can rarely develop a tear as the vitreous base detaches anteriorly and inferiorly during this time
- Biggest risk factor for RT/RD is history of previous RT/RD (in either eye)
- Look for pre-retinal heme inferiorly at vit base!

Retinal Tear (RTs)

- Horseshoe tears (HST) are the most concerning
  - Persistent vitreous traction on flap, most likely to develop RRD
  - Requires urgent laser retinopexy
- Operculated holes
  - No vitreoretinal traction
  - Treatment should not be delayed however is not as urgent as with HST
- Lattice-associated round/atrophic holes
  - Holes at edges of lattice more concerning than holes within lattice

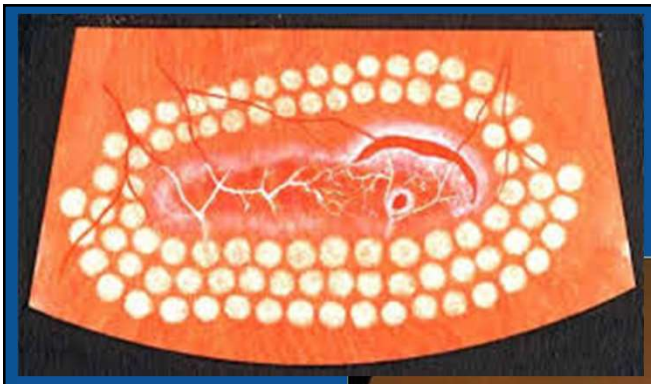

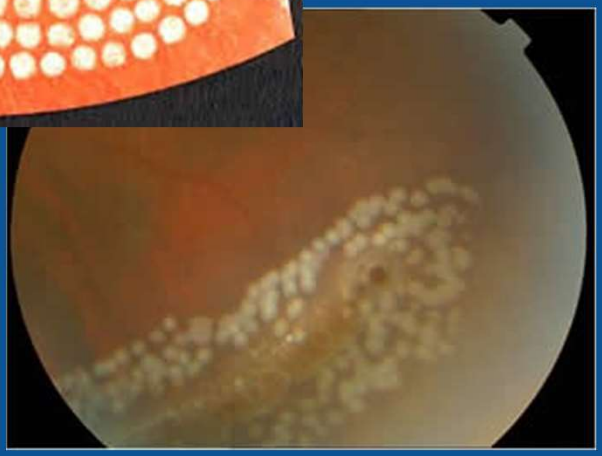

Why treat symptomatic RTs?

- There is a consensus regarding treatment of all HST
- Some treat retinal holes only if symptomatic
- Cataract/refractive surgery can cause "safe" retinal holes to progress to RRD when the eye is manipulated (anterior movement of anterior vitreous cortex/lens)
  - Eliminate possibility of RRD with preventative laser retinopexy particularly when cataract surgery is planned or follow-up is unlikely
- Pigmentation surrounding or within RT indicates chronicity but not adherence to RPE

Endophthalmitis

- Defined as "any severe intraocular inflammation"
- One of the true retinal emergencies
- Can be infectious or non-infectious (sterile)
- Vitrectomy reduces the number of organisms and immune cells, enhances the penetration/diffusion of antibiotics and provides a sample for culture
- Early diagnosis and management is crucial in all cases of endophthalmitis
- Evaluate all patients on POD 1 and any post-op patient complaining of pain

Endophthalmitis

- EVS is dated - used 20g instruments
- Ocular surgery accounts for the vast majority (clear-cornea cataract surgery)
  - NOT recommended to remove IOL
- Current trend is to perform 25g vitrectomy ASAP in nearly all cases of infectious endophthalmitis
- EVS: vision worse than HM, proceed to vitrectomy; if HM or better, "tap and inject" with close follow-up
  - Intravitreal ceftazadime/vancomycin/dexamethasone +/- amphotericin B if fungus suspected
  - Does NOT apply to endogenous, delayed post-op or filtering-bleb related
- If vitrectomy is required, should be performed immediately (middle of the night, if need be)

"tap and inject"

- Requires anesthesia with peribulbar lidocaine
- Do NOT mix the medications in the same syringe as they can precipitate
- Stabilize 25g needle through pars plana with mosquito forcepts and "tap" (aspirate) mid-vitreous with 5cc syringe, then inject meds through same needle without removing from eye
- Requires anterior chamber tap

Vitrectomy in Endophthalmitis

- "less is more"
  - Goal is to debulk vitritis by performing "core" vitrectomy
  - Do NOT attempt PVD creation
  - >10% of cases will have post-operative RD (months to years later)
- Immune cells have released proteolytic enzymes into vitreous leading to retinal necrosis that is easily torn
- Why use steroids?
  - Inflammation suppression far outweighs the potential for enhancement of the infection

Rhegmatogenous Retinal Detachments

- Can cause permanent vision loss/blindness if not appropriately managed
- Treatment options include
  - Barrier laser, pneumatic retinopexy, pars plana vitrectomy
  - I use 25 gauge, sutureless vitrectomy exclusively
  - No need to operate in the middle of the night
    - Problems with OR staffing, availability of equipment, potential errors in gas mixture, etc. can all lead to sub-optimal outcomes
- Scleral buckles are dated, non-superior, painful and cause myopic shift and high % of phoria/tropia
- Critical aspect is the state of the macula
  - "macula on" vs "macula off"; consider OCT

Lincoff's Rule

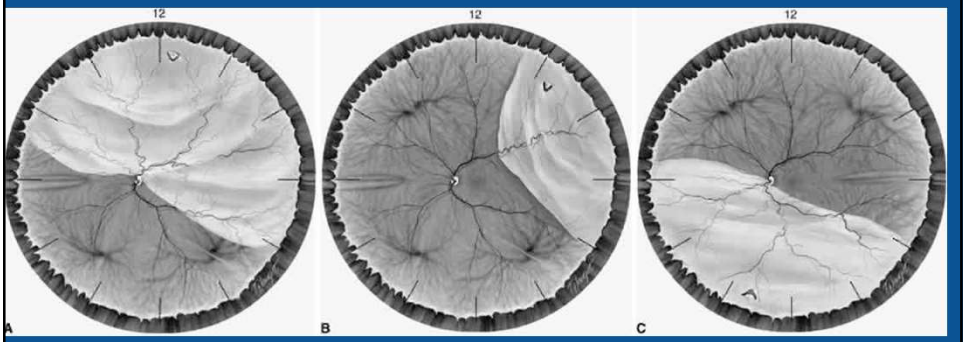

Surgical Goals

- Remove vitreous with meticulous attention to removal of vitreous traction on retinal tears (amputate flaps)
- Drainage of subretinal fluid to re-approximate retina against RPE (fluid-air exchange)
- Perform laser retinopexy around RT (trend is to 360 laser)
- Surface tension management using long-acting gas during air-gas exchange
  - Isovolumetric concentrations of 25% SF6 or 16% C3F8
  - Require surface tension management for at least 14 days
    - Takes 7-14 days for retinopexy to achieve maximal tensile strength

Retinal Tamponade

Superior breaks:

-gas (25% SF6, lasts 2-3 weeks; 16% C3F8, lasts 6 weeks)

-silicone oil (recommended for multiple breaks or inability to maintain head positioning)

Inferior breaks:

- perfluoro-carbon liquid (PFO, remove with separate PPV in 2-3 weeks)

- silicone oil (can easily achieve 100% fill of vitreous cavity)

PVR (proliferative vitreoretinopathy):

- silicone oil

Why is Surface Tension Important?

- "Put the bubble on the trouble", importance of head-positioning management to minimize PSC formation in phakic patients (try to preserve ant hyaloid)
- Prevents the passage of pre-retinal fluid through the RT restoring the transretinal pressure gradient (active suction by RPE)
- If the gas bubble is NOT in contact with the RT, the rhegmatogenous component of the surgery will not be managed (the retinal will re-detach)
- The gas bubble seals the RT even when not in contact with the RPE
  - Allows for restoration of "suction" forces from the RPE allowing retina to re-attach over time
  - Has nothing to do with "pushing" the retina into position

Pneumatic Retinopexy (PR)

- Indications:
  - Ideal: single RT with superior RRD in phasic eye
  - Will attempt PR with any superior RRD with RT(s) within 2 clock hours of each other
  - 70-80% success rate
  - Can perform in motivated temporal/nasal RRD (requires strict head-positioning requirements, often lying down "24-7" for 7-10 days)

PR

- Outcomes are NOT negatively affected if PR fails to attach the retina
- At the very least, the surface tension of the gas bubble prevents expansion of the RRD and will maintain a "macula on" RRD
- Successful PR requires adequate visualization of ALL RTs
  - Less successful in very bullous RRDs or pseudophakic RRDs with the possibility of very small anterior RTs

PR

Use C3F8 gas (100% concentration), 0.6cc to expand to 4x volume (SF6 2x)

- Maintain proper head-positioning and return to clinic 3-4 days later for laser retinopexy of all RT(s) (retina should be attached by then)
  - Cryo used at time of gas injection only if small RT noted and single application of treatment can be used; can potentially exacerbate PVR

Pars Plana Vitrectomy (PPV)

- 90+% success rate for first-time reattachment
- Advantages over scleral buckling:
  - No refractive change, no damage or EOM or levator (no strabimsus/ptosis), much less post-op pain and conjunctival damage, release of all vitreous traction
- Limited indications for scleral buckling in young phakic patients with clear lenses, sectoral RRD with anterior RTs/dialysis, absence of PVR
- Combined PPV w/ SB offers statistically insignificant difference over PPV alone
- Surface tension management with gas, PFO or silicone oil (1000cs)